Journal of Acute Disease

Case Report

jadweb.org

doi: 10.4103/jad.jad_142_24

Left ventricular thrombus in acute cardioembolic stroke: A case report

Vijay Nagappa[1]✉, Shamantha M.C.[2]

[1]*Department of Cardiology, Kasturba Medical College Mangalore, Manipal Academy of Higher Education, Mangalore, India*

[2]*Department of Ophthalmology, K S Hegde Medical Academy, Mangalore, India*

ABSTRACT

Rationale: Although traditionally linked to myocardial dysfunction, left ventricular (LV) thrombus with preserved systolic function presents a distinct diagnostic challenge, necessitating its consideration in all cardioembolic strokes.

Patient's Concern: A 50-year-old woman with diabetes experienced sudden unresponsiveness accompanied by significant right upper limb weakness. Remarkably, her clinical history was devoid of symptoms suggestive of ischemic or arrhythmic cardiac events.

Diagnosis: Advanced neuroimaging identified acute bilateral medial thalamic and paramedian midbrain infarctions. Transthoracic echocardiography revealed an unexpectedly large, mobile LV thrombus, coexisting with normal systolic function (ejection fraction: 60%).

Interventions: Immediate anticoagulation with low molecular weight heparin was initiated, followed by oral warfarin titrated to an international normalized ratio of 2.0-3.0. Physical therapy was implemented to address residual motor deficits.

Outcomes: Three months post-intervention, the patient demonstrated marked neurological improvement (right upper limb power: 3/5) and complete thrombus resolution, confirmed by follow-up echocardiography.

Lessons: This case highlights that LV thrombus is a rare but critical consideration in embolic stroke of uncertain origin, even with normal cardiac function. It underscores the necessity of prompt echocardiography and early anticoagulation to achieve optimal outcomes.

KEYWORDS: Left ventricular thrombus; Embolic stroke; Preserved systolic function; Anticoagulation therapy; Echocardiography

1. Introduction

Left ventricular (LV) thrombus was previously believed to be associated with impaired systolic function in conditions such as myocardial infarction, dilated cardiomyopathy, or ischemic heart disease[1]. However, it is uncommon in patients with preserved systolic function, with an estimated prevalence of less than 1% in this population[2,3]. This is uncommon, and hence, this case is of interest due to novel diagnostic and treatment challenges.

Current medical literature suggests that LV thrombus in preserved LV systolic function is often associated with hypercoagulable states, such as antiphospholipid antibody syndrome, protein C deficiency, and malignancy[4]. Unlike the patients in those reported cases, the patient in this report had no identifiable hypercoagulable state, so a large mobile LV thrombus was particularly unexpected.

Also, despite atrial thrombi being a common source of embolic strokes, this case illustrates the need to include LV thrombus in the differential diagnosis for patients with normal cardiac

✉To whom correspondence may be addressed. E-mail: vijay.nagappa@manipal.edu

This is an open access journal, and articles are distributed under the terms of the Creative Commons Attribution-NonCommercial-ShareAlike 4.0 License, which allows others to remix, tweak, and build upon the work non-commercially, as long as appropriate credit is given and the new creations are licensed under the identical terms.

For reprints contact: reprints@medknow.com

©2025 *Journal of Acute Disease* Produced by Wolters Kluwer-Medknow.

How to cite this article: Nagappa V, M.C. S. Left ventricular thrombus in acute cardioembolic stroke: A case report. J Acute Dis 2025; 14; 20.

Article history: Received 31 December 2024; Revision 28 April 2025; Accepted 28 October 2025; Available online 31 October 2025

function. Early diagnosis and correct anticoagulation therapy, as demonstrated in this report, are paramount in decreasing the chances of fatal complications such as embolic stroke.

2. Case report

A 50-year-old female patient with a known case of diabetes mellitus presented to the emergency department with an acute onset of unresponsiveness. Her family denied any prior symptoms of chest pain, dyspnea, palpitations, or recent infectious illnesses. She was sedentary without known psychosocial stressors and with no history of thromboembolic disorders. The patient has had diabetes for 10 years and has no history of cardiovascular events, stroke, or hypercoagulable states. She also had no family history of thromboembolic events and no history of any previous surgeries or interventions.

Upon admission, the patient was hemodynamically stable, with GCS of E1V1M5. Clinical examination revealed significant motor weakness of the right upper limb (power 1/5) but no other focal neurological deficit. Vital signs were stable with a heart rate of 78 beats per minute (normal: 60-100 bpm), blood pressure 130/80 mmHg (normal: 120-800 mmHg), respiratory rate 16/min (normal: 12-18/min) and oxygen saturation 98% on room air. No superficial venous thrombosis or pedal edema was observed.

The patient manifested her symptoms suddenly on the day of presentation: drowsiness and right upper limb weakness. Subsequent CT brain non-contrast and magnetic resonance imaging with diffusion-weighted imaging on the same day confirmed acute bilateral thalamic infarcts and paramedian midbrain changes. Transthoracic echocardiogram performed the same day showed a large, mobile LV thrombus with preserved systolic function. Explore immediate treatment with low molecular weight heparin was initiated and for seven days. The patient was later started on oral anticoagulation with warfarin at a goal international normalized ratio (INR) of 2.0-3.0. At 3 months of follow-up, the patient showed partial improvement in motor strength, and repeat echocardiography showed complete resolution of the LV thrombus.

Laboratory investigations revealed the following: white blood cell count of 12×10^9/L (normal: 4×10^9/L-10×10^9/L), hemoglobin of 8.1 g/dL (normal: 12-16 g/dL), and platelet count of 491×10^9/ L (normal: 140×10^9/L-440×10^9/L). His serum urea was 26 mg/dL (normal: 6-21 mg/dL) and creatinine was 0.8 mg/dL (normal: 0.59-1.04 mg/dL). Serum electrolytes were as follows: sodium 135 mmol/L (normal: 133-146 mmol/L), potassium 3.9 mmol/L (normal: 3.5-5.1 mmol/L), chloride 95 mmol/L (normal: 95-110 mmol/ L). Her coagulation profile was as follows: activated partial thromboplastin time was 21 s (normal: 25-42 s), prothrombin time was 9 s (normal: 11-15 s) and international normalized ratio was 0.8 (normal: <1.1). His liver function test was unremarkable and negative hypercoagulability panel (antiphospholipid antibodies, protein C and S and factor V Leiden).

Her 12-lead electrocardiogram revealed sinus rhythm with no significant ST-T changes (Figure 1). Neuroimaging: head non-contrast CT showed chronic lacunar infarcts with acute ischemic changes. Cranial magnetic resonance imaging with diffusion-

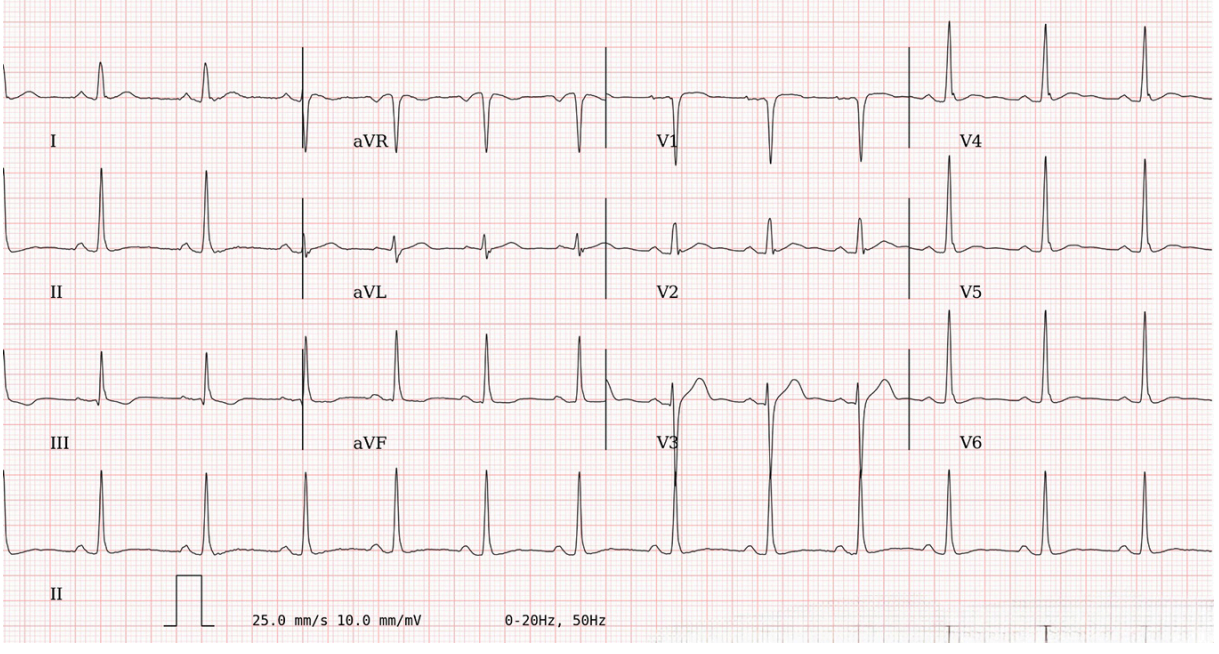

Figure 1. 12-Lead electrocardiogram showing sinus rhythm with no significant ST-T change in a 50-year-old female with acute cardioembolic stroke and a left ventricular thrombus.

weighted imaging showed bilateral thalamic infarcts and acute lacunar infarcts in the right centrum semiovale. Transthoracic echocardiogram revealed a large mobile thrombus in the LV cavity measuring 19×14 mm with preserved systolic function (ejection fraction-60%) (Supplementary Video 1). A 24-hour Holter monitoring was negative for atrial fibrillation and arrhythmias.

The unusual nature of the bilateral thalamic infarcts warranted a search for an embolic source, despite the initial unlikelihood of an LV thrombus due to a lack of typical cardiac risk factors or a hypercoagulable state. Imaging was key to recognizing the thrombus. The eventual diagnosis was a preserved systolic function LV thrombus causing an acute cardioembolic stroke.

Low molecular weight heparin was given in subcutaneous route for 7 days and then converted to oral warfarin with INR target of 2.0-3.0 (with monitoring weekly). The residual motor weakness was treated with physical therapy as supportive therapy. Anticoagulation therapy was continued for 3 months and modified according to follow up imaging studies and clinical progress. There were no surgical or invasive procedures required nor any major changes in therapeutic interventions.

The patient had demonstrated partial recovery of right upper limb strength (power 3/5) at three months. Follow-up echocardiography confirmed complete resolution of LV thrombus (Supplementary Video 2). The patient remained compliant with anticoagulation therapy and was in therapeutic range with INR. To note, no acute or unexpected events happened during the treatment. The patient is being followed closely by cardiology and neurology for potential recurrence or complications.

3. Discussion

Our approach was strengthened by the early identification of an atypical occurrence of bilateral thalamic infarcts as a possible embolic event. Further evaluations with advanced imaging modalities and echocardiography enabled us to accurately identify the source of embolism. Early initiation of anticoagulant therapy was key in preventing further complications and promoting thrombus resolution. However, there are limitations such as no definitive management guidelines available for those with preserved systolic function and potential difficulties in assessing compliance with long-term anticoagulation therapy.

LV thrombus is more commonly described in patients with systolic dysfunction in the medical literature. However, its diagnosis in the presence of preserved function is infrequently reported[2,5]. Previous studies have identified hypercoagulable states, autoimmune disorders, and malignancy as risk factors[4].Our patient did not have any systemic conditions or risk factors identified, as might be seen in similar previously described cases and this case is therefore particularly striking.

Our conclusion is drawn from the successful lysing of the thrombus as well as the partial neurologic recovery seen with antithrombotic therapy. This lends credence to the hypothesis that LV thrombus is a relevant site of embolism, even among patients with preserved systolic function. Hence, clinicians should keep a high index of suspicion in similar presentations.

We conclude that LV thrombus should be considered in the differential diagnosis of unexplained embolic strokes even in the absence of conventional risk factors. It underscores the necessity of timely diagnosis and appropriate anticoagulation therapy to avert severe complications and to improve the outcome. The patient was relieved of having some sort of a final diagnosis and was happy to get the treatment plan without delay. The anticoagulation therapy was a bit of a nuisance, and she was pleased that her symptoms improved slowly but surely. The regular follow-up visits and monitoring helped ensure she would recover and not experience complications again in the future. The patient wanted to underscore the need for full investigations, to make sure rare but treatable conditions like hers are recognized.

Conflict of interest statement

The authors report no conflict of interest.

Ethics approval and consent to participate

This case report was approved by our hospital's local ethics committee and written in accordance with our institutional guidelines. Consent was taken from the appropriate involved parties.

Funding

This study received no extramural funding.

Authors' contributions

Data collection, interpretation of data, original draft preparation and writing: SMC. Conception, design of the work, data collection, review and editing of the manuscript: VN.

Publisher's note

The Publisher of the *Journal* remains neutral with regard to jurisdictional claims in published maps and institutional affiliations.

Edited by Liu JJ

References

[1] Cruz Rodriguez JB, Okajima K, Greenberg BH. Management of left ventricular thrombus: A narrative review. *Ann Transl Med* 2021; **9**(6): 520-520.

[2] Manasrah N, Abdel-Qader A, Al Sbihi A, Alqasem S, Saif LT, Chaudhary AJ, et al. Left ventricular thrombus formation in a structurally and functionally normal heart: A case report and literature review. *J Investig Med High Impact Case Rep* 2022; **10**. doi: 10.1177/23247096221101852.

[3] Svendsen C, Pauley E, Stouffer GA. Left ventricular thrombus formation in the setting of normal systolic function. *JACC Case Rep* 2020; **2**(10): 1470-1474.

[4] Khachatryan A, Harutyunyan H, Psotka M, Batikyan A, Cinar T, Khorsandi M, et al. Hypereosinophilia and left ventricular thrombus: A case report and literature review. *Cureus* 2024. doi: 10.7759/cureus.61674.

[5] Svendsen C, Pauley E, Falk K, Weickert T, Yeung M, Stouffer GA. Patients with left ventricular thrombus despite normal systolic function. *Am J Med Sci* 2021; **362**(2): 198-206.