

Journal of Hainan Medical University

http://www.hnykdxxb.com

Accuracy of screw placement in the apical region of Lenke 1 adolescent idiopathic scoliosis surgery using a calibration technique for the intraoperative navigation error

CHEN Huan-xiong[1], HE Xian-bo[1], LI Guo-jun[1], TANG Song-jie[1], ZHONG Zhen-hao[1], HUANG Tao[1], LIN You-cai[2], LIN Su-yu[2],MENG Zhi-bin[1]✉

1. Department of Spine Surgery, The First Affiliated Hospital of Hainan Medical University, Haikou 570102, China

2. Department of Anesthesiology, The First Affiliated Hospital of Hainan Medical University, Haikou 570102, China

ARTICLE INFO

Article history:
Received 19 Nov 2022
Received in revised form 13 Jan 2023
Accepted 17 Jan 2023
Available online 28 Mar 2023

Keywords:
Adolescent idiopathic scoliosis
Apical region
Pedicle channel classification
Pedicle screw
Navigation error

ABSTRACT

Objective: To study the position and the grade of screw perforation in the apical region of adolescent idiopathic scoliosis (AIS) surgery using a calibration technique for the intraoperative navigation error, and to analyze the related factors of navigation deviation and the clinical significance of the calibration technique. **Methods:** From 2017 to 2020, a total of 60 Lenke 1 AIS surgical cases were enrolled in this research. The 30 cases received surgery using the intraoperative navigation system (Navigation group) and another 30 cases were assisted with intraoperative navigation system with calibration technique (Calibration group) for the intraoperative navigation error. The basic information and radiological data of the both groups were all recorded. According to the Fu Chang-feng′s pedicle channel classification system, the pedicle on the apical region of the two groups was classified. And then the accuracy of screw placement of the two groups was evaluated according to the Rao's classification. **Results:** A total of 600 screws were placed in the two groups. The 297 and 303 pedicle screws were implanted in the navigation group and the calibration group, respectively. In the apical region of the calibration group, the rates of the grade 0 screw placement in type A, B and C pedicle were 95.7%, 86.7% and 68.9% respectively. It was a statistically significant difference from the 73.9%, 66.9% and 30.0% in the navigation group respectively (P<0.05). In the calibration group, the rates of the medial cortical perforation in the type A, B, C and D pedicle were 0%, 1.6%, 1.6% and 0%, respectively. The corresponding rates were 16.3%, 16.9%, 30.0% and 47.6% in the navigation group, respectively. Moreover, in the concave side of the apical region of the calibration group, the rates of the medial cortical perforation in the type A, B, C and D pedicle were 0%, 3.6%, 2.6% and 0%, respectively. Compared with the calibration group, the corresponding rates were higher in the navigation group (34.4%, 25.9%, 37.2% and 60.0%, respectively). No serious complications such as spinal cord or neurovascular injury occurred for the two groups. **Conclusion:** Compared with the intraoperative navigation system, the calibration technique for the intraoperative navigation error could provide the higher accuracy of pedicle screw placement in the apical region of the major curve, the lower medial cortical perforation rate, the less screws misplacement rate on the concave side and the less complication rate of the severe Lenke 1 AIS patients.

1. Introduction

Adolescent Idiopathic Scoliosis (AIS) was a group of three-dimensional deformities of the spine of unknown etiology[1,2]. Patients with severe AIS often have a stenotic deformity in the main curvature of the apical region resulting in difficult screw placement in the apical region and a high risk of screw misplacement[3]. Misplacement of pedicle screws in the main bend apical region could cause serious neurological and vascular damage, therefore, to improve the accuracy of nailing, the anatomical characteristics

✉Corresponding author: MENG Zhi-bin
E-mail: zhibinmeng@163.com.
Fund Project: National Natural Science Foundation of China (81902270); Young Talents′ Science and Technology Innovation Project of Hainan Association for Science and Technology (QCXM202014)

of the pedicle in the paravertebral region and the nailing method have received attention from scholars[4,5]. In recent years, although several studies had shown that computer-assisted navigation could significantly improve the accuracy of heavy AIS stapling, the accuracy of navigation during intraoperative manipulation was susceptible to a number of factors[6]. In 2020, our team proposed a simple navigation calibration technique to monitor navigation offsets in real time, effectively improving the overall AIS pinning accuracy and reducing the medial cortical penetration rate[7]. However, the limitation of this study is the accuracy of analyzing the apical region with pedicle screws.

Therefore, in this study, the arch was classified into types A, B, C, D and E based on the arch typing system of Fu Changfeng *et al*[8], comparing the accuracy and deviation direction of different pedicle types of screws in the apical region of severe AIS with navigation and navigation calibration technology assistance, and analyze the relevant factors of navigation assisted screw displacement and the significance of navigation calibration technology.

2. Materials and methods

2.1 General information

From September 2017 to September 2020 ,A total of 60 patients with severe Lenke type 1 AIS who were treated surgically at our hospital and whose legal guardians had all signed the relevant informed consent were included, including 30 patients in the navigation group, 11 males and 19 females, with a mean age of (14.3±2.52) years, Risser′s sign (3.57±1.17) and preoperative Cobb's angle (75.33±12.22)° . The navigation calibration group included 30 patients, 12 males and 18 females, with a mean age of (14.3±3.62) years, Risser's sign (3.47±0.94) and a preoperative Cobb angle of (77.40±14.89)° .

2.2 Inclusion and exclusion criteria

Inclusion criteria: (1) Patient with severe Lenke type 1 AIS diagnosed by two senior spinal surgeons together; (2) The patients had a full-length coronal Cobb angle of ⩾60° and a vertebral rotation of ⩾1 degree in the parietal region (Nash-Moe method), and all had posterior orthopaedic internal fixation performed by a senior chief surgeon skilled in the use of navigation. Exclusion criteria: (1) Patients with a history of previous spinal surgery or a combination of other spinal conditions such as tumours, tuberculosis and ankylosing spondylitis; (2) Other types of scoliosis; (3) Those with less than 2 years of follow-up and those with incomplete clinical and imaging data.

2.3 surgical methods

(1) Monitoring spinal cord function: Cortical Somatosensory and Motor Evoked Potential (SEP/MEP) neurophysiological monitoring (Medtronic) after general intravenous anaesthesia[9]; (2) Exposure of the fused segment: prone position, routine sterile towel laying, iliac strip taken 2cm below the posterior superior iliac crest, followed by a longitudinal skin incision in the posterior median to expose the spinous process, lamina and tuberosity; (3) Placement navigation calibration positioning: a sterile syringe needle (18G, 0.9 mm inner diameter) was placed into the spinous process in a direction parallel to the long axis of the spinous process, at a depth of 1/2 the length of the spinous process, with the needle holder breaking the end of the needle and the surface of the spinous process exposing an approximately 2 mm round hollow syringe-locating needle (Figure 1A and 1B). However, the navigation group did not have this step; (4) Acquisition and verification of navigation 3D images: ISO-C (Siemens) scan was performed after fixing the reference frame to the spinous process and the scanned images were automatically entered into the navigation system and registration was completed. ① Navigation group: using the navigation probe to verify the consistency of the anatomical landmarks in the surgical field and the position of the anatomical landmarks in the navigation image. ② Navigation calibration group: The navigation probe verifies the consistency of the contact point and the angle between the field positioning needle and the navigation image positioning needle(Figure 1C-1G); (5) Method and sequence of screw placement: ① Navigation group: Guided by the guidance of navigation, selecting the optimal point, the horizontal angle and the sagittal angle of the pedicle screws, and the high-speed grinding drill is used to prepare the pedicle screws track. After the scouting survey determines that the pedicle screws track is a bony structure, taping and implanting the screws. The order of screw placement is from far to near the reference frame, first left and then right, alternately screw placement. The nailing process is carefully handled to avoid displacement of the spine or reference frame. Navigation calibration group: The method is the same as the navigation group, but the navigation image verification of the adjacent positioning pins is required before placing the pedicle screws. Such as when positioning pin navigation image point offset <2 mm or angular offset <5° , You need to adjust the pedicle screws point and angle accordingly; If the navigation image point offset is ⩾2 mm or the angular offset is ⩾5° (Figure 1H-1J), checking whether the reference frame is loosed, shifted, or the transmission path is blocked. And the you can perform the navigation scan again or refer to the navigation 3D image; (6) Three-dimensional correction: After facet joint fusion, the correction was performed by rotating the rod, pressing, stretching, and directly rotating. The lamina was decor, and the autogenous sacrum was bone grafted. Finally, the drainage tube was placed, and the incision was sutured layer by layer.

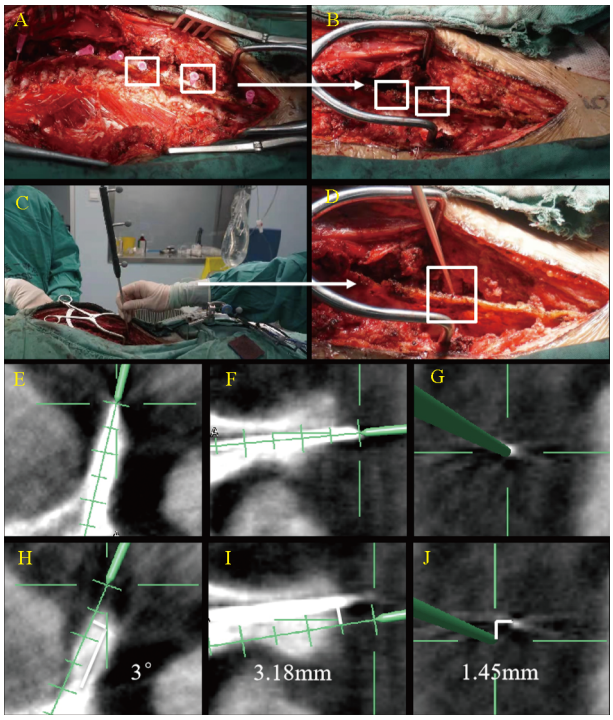

A: Placement of sterile injection needle into the spinous process; B: The end of the sterile needle was removed to make a positioning needle; C-D: Navigation probe tip embedded in positioning pin for image calibration; E-G: Navigation images in the horizontal, sagittal and coronal planes showed the navigation probe in the same direction as the positioning needle, with no image shift in navigation; H-J: The navigation image showed the orientation and angle of the navigation offset, with the horizontal image indicating a 3 degree clockwise rotation of the navigation offset; the sagittal image indicated a 3 mm caudal navigation offset and the coronal image indicates a 1 mm left navigation offset.

Fig 1 Diagram of navigation calibration positioning pin

2.4 Evaluation criteria

Classifying the arch roots in the apical region of severe AIS based on the arch root typing system of Fu Changfeng *et al*[8]. Type A: cancellous bone in the isthmus of the vertebral arch ⩾3 mm in width; Type B: cancellous bone in the isthmus of the vertebral arch < 3 mm in width; Type C: cortical bone passage in the isthmus of the vertebral arch, but sclerosis without cancellous bone; Type D: sclerosis in the isthmus of the vertebral arch and no cortical bone passage. type D- Ⅰ: the outer edge of the arch and the outer edge of the vertebral body have a "C" shape; type D- Ⅱ: the outer edge of the arch and the outer edge of the vertebral body have a "I" shape; type E: the arch is absent (Figure 2). The position of the pedicle screw in the apical region of patients with AIS was assessed according to the postoperative CT scan, the direction of screw penetration through the bone cortex was recorded and the distance of penetration through the bone cortex was measured. The degree of cortical penetration was assessed according to the Rao classification[10]: Grade 0, where the screw did not penetrate the pedicle or vertebral cortex; grade 1, where the penetration distance was <2 mm; grade 2, where the penetration distance was 2-4 mm; and grade 3, where the penetration distance was >4 mm (Figure 3A-3D). The location of arch root penetration was classified according to[11]: medial, lateral cortical penetration, anterior vertebral wall or intervertebral foramen penetration (Figure 3E-3H).

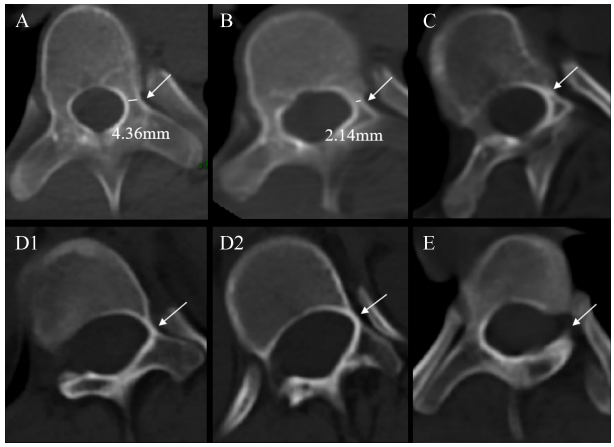

A: type A arch; B: type B arch; C: type C arch; D1: type D-I arch; D-2: type D-II arch; E: type E arch.

Fig 2 Pedicle classification

2.5 Statistical analysis

All analyses were performed using SPSS software (SPSS 26.0; IBM, Armonk, NY, USA), with continuous variables expressed as $\bar{x}\pm s$, and a *t*-test was used for comparison of measurement data between two groups. The rates were compared using the chi-square test and the difference was statistically significant at $P<0.05$.

3. Results

3.1 General situation

Sixty patients were included in this study, 30 in the navigation group versus and 30 in the navigation calibration group. In the navigation group, the mean Cobb Angle before surgery was (75.33±12.22)°, the mean Cobb Angle after surgery was (14.50±9.49)°, and the main bending correction rate was (81.35±9.45)%. However, the preoperative and postoperative main bend Cobb angle and orthosis rates were (77.40±14.89)°, (15.25±11.65)° and (81.53±10.90)% in the navigation calibration group respectively, with no statistically significant difference between the two groups. The mean number of nails placed in the parietal region was (9.77±0.63) in the navigated group compared to (9.87±0.43) in the navigated calibrated group, with no statistically significant difference between the two groups either (P=0.182). In addition, gender, age and Risser's sign were not statistically significant in either group (Table 1).

3.2 Accuracy of pedicle screw placement in the apical region

A total of 600 pedicle screws were placed in the parietal region in both groups, 297 in the navigation group and 303 in the calibration group (Table 2). The rates of pedicle screw placement in the

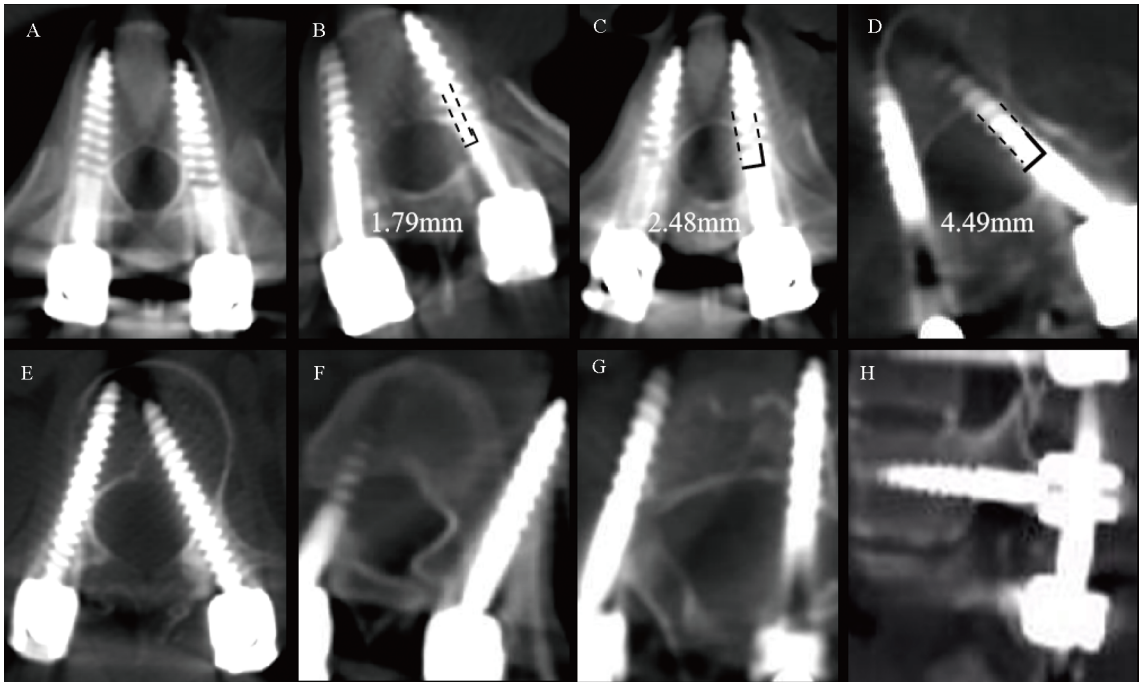

A: Grade 0 is an intrapedicular screw without perforation; B: Grade 1, perforations <2 mm; C: Grade 2, perforations 2-4 mm; D: Grade 3, perforations > 4 mm, E: Medial cortical perforation; F: Lateral cortical perforation; G: Anterior cortical perforation; H: Foraminal perforation.

Fig 3 The grade and the position of perforation

Tab 1

Clinical and radiological data of patients of two groups (n=30, $\bar{x}$±s)

Parameters	Navigation group	Calibration group	x^2/t	P
Gender (n, male/female)	11/19	12/18	0.261	0.606
Age (years)	14.30±2.52	14.03±3.26	0.354	0.872
Risser sign	3.57±1.17	3.47±0.94	0.366	0.362
Preoperative Cobb angle of the major curve (°)	75.33±12.22	77.40±14.89	-0.588	0.706
Postoperative Cobb angle of the major curve (°)	14.50±9.49	15.25±11.65	-0.270	0.342
Cobb angle correction ratio (%)	81.35±9.45	81.53±10.90	43.314	0.585
Number of nails in the apical region	9.77±0.63	9.87±0.43	-0.719	0.182

navigation calibration group were 95.7%, 86.7% and 68.9% for the A, B and C pedicle 0 levels respectively, which were significantly higher than those in the navigation group (73.9%, 66.9% and 30.0%), with statistically significant differences between the two groups (P values of 0.007, 0.040 and 0.001 respectively). In addition, the misplacement rates for type B, C and D pedicle 2 screws were 7.1%, 9.8% and 0.0% in the navigation calibration group, respectively, all significantly lower than the 21.8%, 33.3% and 61.9% in the navigation group, with statistically significant differences between the two groups (P values of 0.002, 0.009 and 0.001, respectively). On the concave side of the apical region, the placement rate of type A pedicle level 0 screws was 91.7% significantly higher in the navigated calibration group than in the navigated group at 53.1%, while the misplacement rates of type B, C and D pedicle level 2 screws were 12.5%, 12.8% and 5.3% respectively in the navigated calibration group, which were significantly lower than those of the navigated group at 29.3%, 41.9% and 66.7%, with statistically significant differences between the two groups (P values of 0.040, 0.018, 0.010 and 0.001 respectively). In contrast, the number of type E pedicles was too small to be statistically significant and was therefore not included in the statistical analysis.

3.3 Misplacement of screws in the apical region in the direction of penetration

A total of 172 screws penetrated the cortex in both groups, 124 on the concave side and 48 on the convex side. The distribution of cortical penetration by different types of pedicle placement screws between the two groups in the parietal region was detailed in Figure 4. The rates of medial cortical penetration by type A, B, C and D pedicle screws in the parietal region were 0%, 1.6%, 1.6% and 0% in the navigated calibration group, which were lower than the rates of 16.3%, 16.9%, 30.0% and 47.6% in the navigated group. Meanwhile, the rates of penetration of the medial cortex by the type A, B, C and D pedicle placement screws were 0%, 3.6%, 2.6% and 0% in the concave navigated calibration group in the parietal region, significantly lower than the 34.4%, 25.9%, 37.2% and 60% in the navigated group, with statistically significant differences between the two groups (P values of 0.004, 0.014, 0.002 and 0.002, respectively). However, the difference in the rate of cortical penetration by pedicle screws between the two groups on the convex side of the parietal region was not statistically significant (Table 3).

Tab 2
Distribution of screws position in the apical region [*n* (%)]

Pedicle classification	Navigation group					Calibration group				
	Grade 0	Grade 1	Grade 2	Grade 3	Total	Grade 0	Grade 1	Grade 2	Grade 3	Total
Bilateral										
Type A	68(73.9)	13(14.1)	10(10.9)	1(1.1)	92(100)	88(95. 7)*	2(2.2)	1(1.1)	1(1.1)	92(100)
Type B	83(66.9)	8(6.5)	27(21.8)	6(4.8)	124(100)	108(85.7)*	5(4.0)	9(7.1)*	4(3.2)	126(100)
Type C	18(30.0)	20(33.3)	20(33.3)	2(3.3)	60(100)	42(68.9)*	7(11.5)	6(9.8)*	6(9.8)	61(100)
Type D	4(19.0)	1(4.8)	13(61.9)	3(14.3)	21(100)	17(70.8)*	6(25.0)	0(0.0)*	1(4.2)	24(100)
Type E	0(0.0)	0(0.0)	0(0.0)	0(0.0)	0(0.0)	0(0.0)	0(0.0)	0(0.0)	0(0.0)	0(0.0)
Total	173(58.2)	42(14.1)	70(23.6)	12(4.0)	297(100)	255(84.2)	20(6.6)	16(5.3)	12(4.0)	303(100)
Concave side										
Type A	17(53.1)	9(28.1)	5(15.6)	1(3.1)	32(100)	33(91.7)*	2(5.6)	0(0.0)	1(2.8)	36(100)
Type B	33(56.9)	4(6.9)	17(29.3)	4(6.9)	58(100)	43(76.8)	3(5.4)	7(12.5)*	3(5.4)	56(100)
Type C	13(30.2)	10(23.3)	18(41.9)	2(4.7)	43(100)	23(59.0)	6(15.4)	5(12.8)*	5(12.8)	39(100)
Type D	4(26.7)	0(0.0)	10(66.7)	1(6.7)	15(0.0)	12(63.2)	5(26.3)	1(5.3)*	1(5.3)	19(100)
Type E	0(0.0)	0(0.0)	0(0.0)	0(0.0)	0(0.0)	0(0.0)	0(0.0)	0(0.0)	0(0.0)	0(0.0)
Total	67(45.3)	23(15.5)	50(33.8)	8(5.4)	148(100)	111(74.0)	16(10.7)	13(8.7)	10 (6.7)	150(100)
Convex side										
Type A	51(85.0)	4(6.7)	5(8.3)	0(0.0)	60(100)	55(98.2)	0(0.0)	1(1.8)	0(0.0)	56(100)
Type B	50(75.8)	5(7.6)	9(13.6)	2(3.0)	66(100)	65(92.9)	3(4.3)	1(1.4)	1(1.4)	70(100)
Type C	5(29.4)	10(58.8)	2(11.8)	0(0.0)	17(100)	19(86.4)*	1(4.5)*	1(4.5)	1(4.5)	22(100)
Type D	0(0.0)	0(0.0)	4(66.7)	2(33.3)	6(100)	5(100.0)	0(0.0)	0(0.0)	0(0.0)	5(0.0)
Type E	0(0.0)	0(0.0)	0(0.0)	0(0.0)	0(0.0)	0(0.0)	0(0.0)	0(0.0)	0(0.0)	0(0.0)
Total	106(71.1)	19(12.8)	20(13.4)	4(2.7)	149(100)	144(94.1)	4(2.6)	3(2.0)	2(1.3)	153(100)

Note: Comparison of the degree of arch root penetration between the two groups A, B, C, D and E. *indicates a statistically significant difference, $P<0.05$.

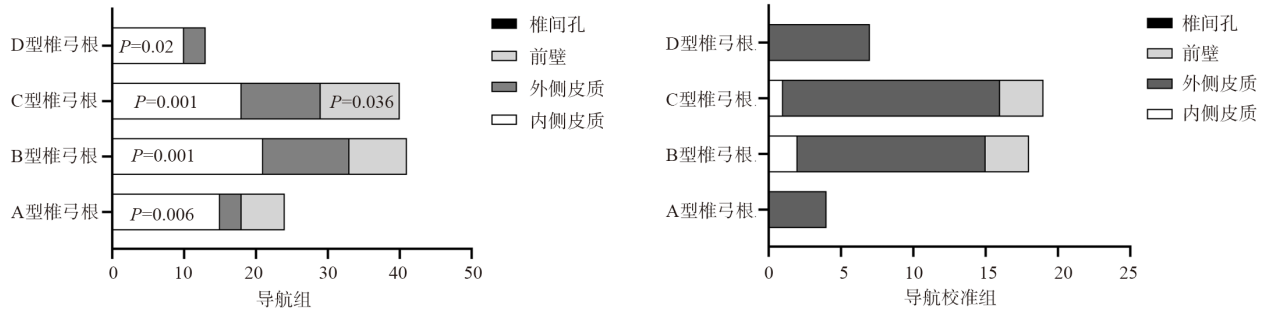

Fig 4 The position and the numbers of misplaced screw divided into A-D pedicle classification between the two groups

Tab 3
Distribution of violated cortex by misplaced screw in the apical region [*n* (%)]

Pedicle classification	Navigation group					Calibration group				
	Medial	Lateral	Anterior	Foraminal	Total	Medial	Lateral	Anterior	Foraminal	Total
Concave side										
Type A	11(34.4)	2(5.9)	2(5.9)	0(0.0)	15(46.9)	0(0.0)*	3(8.3)	0(0.0)	0(0.0)	3(8.3)
Type B	15(25.9)	5(8.6)	5(8.6)	0(0.0)	25(43.1)	2(3.6)*	8(14.3)	3(5.4)	0(0.0)	13(23.2)
Type C	16(37.2)	5(11.6)	9(20.9)	0(0.0)	30(69.8)	1(2.6)*	13(33.3)	2(5.1)*	0(0.0)	16(41.0)
Type D	9(60.0)	0(0.0)	2(13.3)	0(0.0)	11(73.3)	0(0.0)*	7(36.8)*	0(0.0)	0(0.0)	7(36.8)
Type E	0(0.0)	0(0.0)	0(0.0)	0(0.0)	0(0.0)	0(0.0)	0(0.0)	0(0.0)	0(0.0)	0(0.0)
Total	51(34.5)	12(8.1)	18(12.2)	0(0.0)	81(54.7)	3(2.0)	31(20.7)	5(3.3)	0(0.0)	39(26.0)
Convex side										
Type A	4(6.7)	1(1.7)	4(6.7)	0(0.0)	9(15.0)	0(0.0)	1(1.8)	0(0.0)	0(0.0)	1(1.8)
Type B	6(9.1)	7(10.6)	3(4.5)	0(0.0)	16(24.2)	0(0.0)	5(7.1)	0(0.0)	0(0.0)	5(7.1)
Type C	2(11.1)	6(35.3)	4(23.5)	0(0.0)	12(70.6)	0(0.0)	2(9.1)	1(4.5)	0(0.0)	3(13.6)
Type D	1(16.7)	3(50.0)	2(33.3)	0(0.0)	6(100)	0(0.0)	0(0.0)	0(0.0)	0(0.0)	0(0.0)
Type E	0(0.0)	0(0.0)	0(0.0)	0(0.0)	0(0.0)	0(0.0)	0(0.0)	0(0.0)	0(0.0)	0(0.0)
Total	13(8.7)	17(11.4)	13(8.7)	0(0.0)	43(28.9)	0(0.0)	8(5.2)	1(0.6)	0(0.0)	9(5.9)

Note: Comparison of the direction of penetration of the two groups of screws in the apical region at the medial and lateral sides of the A-E pedicle, the anterior wall of the vertebral body and the intervertebral foramen. *indicates a statistically significant difference, $P<0.05$.

3.4 complications

No serious complications such as spinal cord or vascular injuries occurred during the perioperative period in either group. However, a postoperative CT scan of one patient in the navigation group revealed one screw on the concave side of the main thoracic curve off-side and immediately adjacent to the aorta, 1.5 mm away from it. One patient in the navigation calibration group had an alarm on the SEP/MEP neurophysiological monitor during intraoperative orthopaedics, and the wave amplitude of the neurophysiological monitor returned to normal after stopping the operation, and the patient showed no signs of nerve damage after the operation. Patients in both groups were followed up for 25 to 36 months after surgery, with a mean of 30.5 months, and no screw loosening, broken nails or broken rods occurred in either group. The imaging data and appearance of typical cases in the navigation calibration group are shown in Figure 5A-5J.

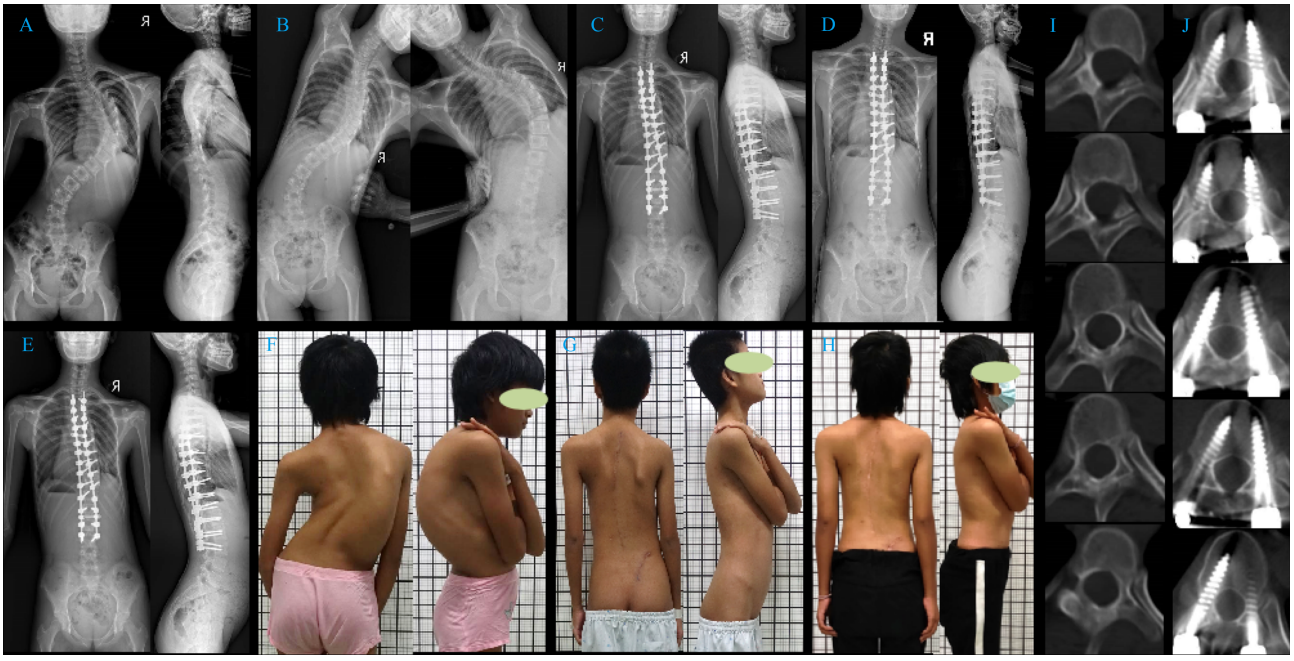

A: Preoperative full-length frontal view of the spine: main thoracic curve 101°. B: Pre-operative prone bending film. C: 7 d post-operative standing full-length frontal and lateral views of the spine: main thoracic curve reduced to 10°, main curve correction rate 90%. D-E: Post-operative follow-up at 1 and 2 years showed good orthopaedic results in full-length ortholateral position, with no broken nails or rods. F~H: Pre-operative, 14 da post-operative and 2 years post-operative views, after which the patient's razorback deformity was eliminated and the trunk was balanced. I: Preoperative arch morphological features of the apical region. J: Post-operative follow-up CT showed no cortical penetration of the pedicle screws in the apical region.

Fig 5 Radiological data of a demo case with calibration technique in intraoperative navigation error

4. Discussion

In this study, the arch roots in the parietal region of severe AIS were divided into types A-E and then compared the accuracy and deflection of the different arch root types with the aid of navigation and navigation calibration techniques. The results of the study showed that the navigated calibration group was more accurate in nailing the A, B and C pedicles in the apical region than the navigated group and reduced the rate of misplacement of the concave pedicle screws as well as reducing the rate of medial cortical penetration of the A, B, C and D pedicles. Thus, intraoperative navigation calibration techniques could improve the accuracy of nailing in the parietal region of severe AIS compared to navigation alone. However, the issue of intraoperative navigational offset is also worthy of attention and study in order to further improve the accuracy of nailing in the parietal region of patients with AIS.

4.1 Factors affecting the offset of severe AIS screw placement with navigation assistance

The causes of intraoperative navigational excursions are manifold: (1) Positioning accuracy of navigation equipment. Masashi *et al*[12], in a study of the calibration accuracy required for navigation-based systems in AIS orthopaedics, reported that the rate of pedicle screw penetration for assisted placement with a navigation calibration accuracy >0.5 mm was significantly greater than that with a calibration accuracy <0.5 mm. However, the Iso-C 3D navigation

point offset was (0.5±0.48) mm and the angular offset was (1±0.83)° [13]. Therefore, to improve the accuracy of the AIS nail placement, an intraoperative adjustment of the Iso-C 3D navigation accuracy offset of <0.5 mm is required. (2) Severe anatomical abnormalities in the apical region of the AIS. The presence of anatomical deformities such as pedicle stenosis and vertebral rotation in the apical region of severe AIS leads to deviation of the screw placement from its normal anatomical position[14]. Sarwahi *et al*[15] showed that the incidence of navigation-assisted misplaced screws in abnormal pedicles was three times higher than in normal pedicles. Also, the rotation of the vertebrae could reduce the accuracy of the navigation[16]. The anomalous anatomy of the parietal vertebral region of heavy AIS was therefore also a factor in the accuracy of navigation. (3) Shifting and obscuring of the navigation reference frame. The infrared reflecting sphere of the reference frame and navigation probe could cause a shift in navigation when it gotten blood on it intraoperatively, when it was badly worn or when the transmission path was obscured[7]. Oba *et al*[17] also suggested that in patients with AIS the spinous process was immature and that the navigation reference frame could be loosened and displaced when it was clamped to the spinous process, resulting in a shift in navigation. (4) Spinal displacement, intraoperative shift of the target vertebra relative to the reference frame during operations such as nail entry point opening, nail tract opening, tapping and nail placement, resulting in a change in the three-dimensional spatial position corresponding to the navigational reference frame[18]. In this study, patients with severe AIS had relatively high flexibility and immature spinous processes in the parietal region, which caused the vertebral body and spinous processes in the apical region to vibrate during intraoperative manipulation of the pedicle, opening, tapping and nailing, causing loosening of the navigational reference frame and changed in the three-dimensional space of the spine, resulting in navigational drift.

4.2 The effect of navigation calibration techniques on the placement of screw in the apical region of severe AIS

The presence of an arch stenosis deformity, vertebral rotation and spinal cord deviation in the apical region of severe AIS resulted in a high rate of pedicle screw misplacement and a high risk of screw placement in the parietal region[19,20]. In order to improve the accuracy of screw placement in the apical region of patients with severe AIS and to reduce navigation drift and screw misplacement causing severe spinal cord nerve and vascular injury, this research team proposed a navigation calibration technique[7]. The navigation calibration technique involves placing the caudal end of the injection needle into the spine of the target vertebra so that it became integral with the target vertebra, creating a navigation positioning needle that the surgeon inserts into the positioning needle for real-time calibration of navigation accuracy. The operator needed to verify the accuracy of the navigation before intraoperative screw placement. If the accuracy of the navigation was shifted, the position and angle of the navigation into the nail could be adjusted according to the results of the verification. This allowed real-time monitoring of the loosening of the navigation reference frame or the three-dimensional spatial changed between the navigation reference frame and the spine due to spinal vibration during the last target nailing operation. In addition, during the preparation of the navigation needle, the angle of the needle into the spinous process could be adjusted according to the direction of rotation of the vertebral body, and the angle of the needle into the spinous process should have been parallel to the direction of spinous rotation. In this study, the rate of 0-level nailing was significantly higher in the navigated calibration groups A, B, C and D than in the navigated group, while the rate of medial cortical breakage of screws was significantly lower in the navigated calibration groups A, B, C and D on the concave side of the apical region than in the navigated group. Thus, compared to navigation-assisted nailing in the apical region of severe AIS alone, the navigation calibration technique allowed for real-time intraoperative calibration of the navigation offset, improved the accuracy of screw in the apical region of severe AIS, and reduced the rate of medial cortical penetration.

4.3 Limitations of this study

Limitations of this study: (1) Single-centre studies with retrospective, non-randomised inclusion of subjects, with later, rigorously designed, prospective, randomised, large-sample multicentre studies needed to obtain a more reliable basis and conclusions. (2) Although navigation calibration techniques can monitor navigation excursions in real time, the accuracy of pin placement after adjustment for distance and angle of excursion depends to some extent on the operator's understanding of navigation principles. Therefore, at a later stage, an infrared anti-sphere can be mounted on the positioning pin to track the movement of the target vertebrae, which can be combined with navigation 3D matching calibration techniques to correct the navigation offset problem. (3) Only patients with severe Lenke type 1 AIS were included in this study; subsequent studies may include patients with other types of scoliosis.

In conclusion, the intraoperative navigation drift calibration technique improved the accuracy of screw in the apical region of severe Lenke type 1 AIS, reduced the rate of medial cortical penetration, decreased the rate of concave pedicle misplacement and increased the safety of nailing in the apical region of patients with severe AIS compared to navigation alone.

References

[1] Chen H, Yang KG, Zhang J, et al. Upregulation of microRNA-96-5p is associated with adolescent idiopathic scoliosis and low bone mass phenotype. *Sci Rep* 2022, **12**(1): 1-12.

[2] Chen H, Zhang J, Wang Y, et al. Abnormal lacuno-canalicular network and negative correlation between serum osteocalcin and Cobb angle indicate abnormal osteocyte function in adolescent idiopathic scoliosis. *FASEB J* 2019, **33**(12): 13882-13892.

[3] Guzek RH, Mitchell SL, Krakow AR, et al. Morphometric analysis of the proximal thoracic pedicles in Lenke II an d IV adolescent idiopathic scoliosis: An evaluation of the feasibility for pedicle screw insertion. *Spine Deform* 2021, **9**(6): 1541-1548.

[4] Bartley CE, Yaszay B, Bastrom TP, et al. Perioperative and delayed major complications following surgical treat ment of adolescent idiopathic scoliosis. The Journal of bone and joint surgery. *J BoneJoint Surg Am* 2017, **99**(14): 1206-1212.

[5] Tanaka M, Fujiwara Y, Uotani K, et al. C-arm-free anterior correction for adolescent idiopathic scoliosis (Lenke type 5C): Analysis of early outcomes and complications. *World Neurosurg* 2021, **150**: e561-e569.

[6] Rahmathulla G, Nottmeier EW, Pirris SM, et al. Intraoperative image-guided spinal navigation: Technical pitfalls and their avoidance. *Neurosurg Focus* 2014, **36**(3): E3.

[7] Chen HX, Huang T, Li GJ, et al. Accuracy of pedicle screw placement in Lenke 1 adolescent idiopathic scoliosis surgery using intraoperative navigation with a simple calibration technique. *J Hainan Med Univ* 2020, **26**(3): 7.

[8] Fu CF, Wang ZY, Liu Y. Morphologic classification of thoracic pedicles in various types of scoliosis. *J Spinal Surg* 2010, (**2**): 99-102.

[9] Meng ZB, Pang XY, Li J, et al. Efficacy and safety of motion evoked potential combined with electromyogram in minimally invasive transforaminal lumbar intervertebral fusion. *J Spinal Surg* 2019, **17**(1): 37-41.

[10]Rao G, Brodke DS, Rondina M, et al. Comparison of computerized tomography and direct visualization in thoracic pedicle screw placement. *J Neurosurg* 2002, **97**(2): 223.

[11]Abul-Kasim K, Strömbeck A, Ohlin A, et al. Reliability of low-radiation dose CT in the assessment of screw placement after posterior scoliosis surgery, evaluated with a new grading system. *Spine* 2009, **34**(9): 941.

[12]Uehara M, Takahashi J, Ikegami S, et al. How much surface registration accuracy is required using CT-based navigation system in adolescent idiopathic scoliosis surgery?. *Clin Spine Surg* 2019, **32**(3): E166-E170.

[13]Geerling J, Gösling T, Gösling A, et al. Navigated pedicle screw placement: Experimental comparison between CT- and 3D fluoroscopy-based techniques. *Comput Aided Surgery* 2008, **13**(3): 157-166.

[14]Brink RC, Schlösser TPC, Colo D, et al. Asymmetry of the vertebral body and pedicles in the true transverse plane in adolescent idiopathic scoliosis: A CT-based study. *Spine Deform* 2017, **5**(1): 37-45.

[15]Sarwahi V, Sugarman EP, Wollowick AL, et al. Prevalence, Distribution, and surgical relevance of abnormal pedicles in spines with adolescent idiopathic scoliosis vs. no deformity: A CT- based study. *J Bone Joint Surg Am* 2014, **96**(11): e92.

[16]Ishikawa Y, Kanemura T, Yoshida G, et al. Intraoperative, full-rotation, three-dimensional image (O-arm)-based n avigation system for cervical pedicle screw insertion. *J Neurosurg Spine* 2011, **15**(5): 472-478.

[17]Oba H, Ebata S, Takahashi J, et al. Pedicle perforation while inserting screws using O-arm navigation during surgery for adolescent idiopathic scoliosis: Risk factors and effect of insertion order. *Spine* 2018, **43**(24): E1463-E1468.

[18]Zhang HL, Zhou DS, Jiang ZS, et al. Accuracy of computer-assisted cervicle pedicle screw installation. *Bull A cad Mil Med Sci* 2009, **33**(2): 157-160.

[19]Castelein RM, Pasha S, Cheng JC, et al. Idiopathic scoliosis as a rotatory decompensation of the spine. *J Bone Miner Res* 2020, **35**(10): 1850-1857.

[20]Davis CM, Grant CA, Pearcy MJ, et al. Is There asymmetry between the concave and convex pedicles in adolescent idiopathic scoliosis? A CT Investigation. *Clin Orthop Relat Res* 2017, **475**(3): 884-893.